



PATIENT PRESENTING CLINICAL SIGNS

Max Smith History: Decreased appetite, ADR, PU/PD, painful abdomen. Has been on Caninsulin, Apoquel, Cerenia, Recently Clavaseptin, Mirtazapine

SPECIES Abnormal PE/Chem/CBC/UA Results: Cbc unremarkable. Pre-and postprandial serum bile acids normal. Spec cPL normal

Canine

ULTRASONOGRAPHIC EXAMINATION OF THE ABDOMEN

BREED *Urinary System*

Dachshund The urinary bladder and visible portion of the pelvic urethra are normal for the degree of luminal distension. The urine is anechoic with no evidence of debris. Cystic calculi and discrete masses are not observed. The region of the trigone and visible portion of the proximal urethra are normal.

SEX

Neutered Male The prostate is normal in size (0.66 cm in width) and shape. Parenchyma is homogenous. The prostatic urethra appears normal without evidence of dilation or obstruction.

AGE

14 years The left kidney is normal in size (4.75 cm in length) with a normal shape, architecture and smooth peripheral margins. The cortex is hyperechoic relative to the spleen. There is a normal 1:3 cortex to medulla ratio with mild to moderate loss of corticomedullary distinction. There is no evidence of pyelectasia, nephroliths, infarcts or hydroureter. Renal vasculature is normal.

WEIGHT

8.24 kg The right kidney is normal in size (4.64 cm in length) with a normal shape, architecture and smooth peripheral margins. The cortex is hyperechoic relative to the spleen. There is a normal 1:3 cortex to medulla ratio with mild to moderate loss of corticomedullary distinction. There is no evidence of pyelectasia, nephroliths, infarcts or hydroureter. Renal vasculature is normal.

INTERPRETED BY

Andrea Nicastro, DVM,
Diplomate ACVIM (*Small
Animal Internal Medicine*)

Adrenal Glands

The left adrenal gland is mildly enlarged (0.43 cm at cranial pole) (0.68 cm at caudal pole) (1.73 cm in length) with a normal shape and homogenous parenchyma. The glandular echogenicity and detail are unremarkable. Capsule, cortex, and medullary definition are normal. The phrenicoabdominal vein and surrounding vasculature appears normal.

IMAGING PERFORMED BY

Crystal Hill

The right adrenal gland is mildly enlarged (1.01 cm at cranial pole) (0.66 cm at caudal pole) (2.15 cm in length) with a normal shape and homogenous parenchyma. The glandular echogenicity and detail are unremarkable. Capsule, cortex, and medullary definition are normal. The phrenicoabdominal vein and surrounding vasculature appears normal.

HOSPITAL NAME

Hartzel AH

Spleen

The spleen is subjectively normal in size (1.45 cm in width at the level of the hilus) with slightly undulating peripheral contours. There is appropriate echogenicity and echotexture. Pinpoint hyperechoic-to-mineralized foci are observed throughout the organ. Splenic vasculature appears normal.

REFERRING VET

Morris

Liver

The liver is subjectively enlarged with slightly swollen peripheral contours. The parenchyma is isoechoic relative to the spleen and diffusely homogeneous in appearance. No distinct focal lesions are observed. Vascular and biliary tracts are of normal volume with no evidence of congestion.

INVOICE

13949

The gall bladder is moderately distended. The wall is normal in thickness. Several polypoid-like lesions are observed along the luminal surface. A moderate amount of aggregated, echogenic-to-mineralized, partially dependent debris/sludge is observed within the lumen. The cystic and common bile ducts are normal/not seen.

DATE

8.3.23

Gastrointestinal



PATIENT

Max Smith

The stomach and intestine are free of stasis and exhibit normal peristaltic activity. The gastric lumen is mildly distended with ingesta. The gastric wall and pylorus are normal in thickness with a normal layering pattern. The pyloric outflow tract is patent. The small intestinal lumen is not dilated. The small intestinal wall is normal in thickness with a normal layering pattern and appropriate mural detail. Discreet masses are not identified. The colonic wall is normal. There is no evidence of an obstructive pattern.

SPECIES

Canine

Pancreas

The right limb of the pancreas is visible with normal curvilinear peripheral contours. The parenchyma is largely isoechoic relative to surrounding omental fat and slightly mottled in appearance. The pancreatic duct is visible but not overtly dilated. There is no evidence of peripancreatic inflammation or effusion.

BREED

Dachshund

Free Abdomen

The peritoneal cavity is normal. There is no evidence of inflammation or effusion. The abdominal lymph nodes are normal/not visible.

SEX

Neutered Male

ULTRASONOGRAPHIC FINDINGS

AGE

14 years

Primary Findings

- Mild bilateral adrenomegaly
- The hepatic changes are most consistent with a diabetes hepatopathy. However, inflammatory disease, infiltrative neoplasia, or other hepatopathies cannot be completely excluded. Correlation with the patient's liver values is recommended. It should be noted that the liver enzyme values were not included with the history.

WEIGHT

8.24 kg

Secondary Findings

- Bilateral chronic age-related renal changes
- The splenic changes are most consistent with dystrophic mineralization. This is likely a benign incidental finding, often seen with endocrinopathies.
- The pancreatic changes are most consistent with age-related parenchymal remodeling, potentially secondary to a prior inflammatory episode, early fibrosis or chronic pancreatitis.
- The gallbladder changes could be consistent with fasting, cholestasis, or an emerging mucocele.

INTERPRETED BY

Andrea Nicastro, DVM,
Diplomate ACVIM (*Small Animal Internal Medicine*)

IMAGING PERFORMED BY

Crystal Hill

HOSPITAL NAME

Hartzel AH

INTERPRETATION OF THE FINDINGS & FURTHER RECOMMENDATIONS

REFERRING VET

Morris

- Given the patient's diabetic status and painful abdomen, consider a urine culture and sensitivity to assess for occult infection.
- Orthopedic and neurologic examinations are also recommended to assess for nonmetabolic causes of pain.

INVOICE

13949

- If the patient's diabetic status is not regulated, a glucose curve is recommended to determine if an insulin dose adjustment is indicated.

DATE

8.3.23

- If the patient appears insulin-resistant, further testing for hyperadrenocorticism (i.e., low-dose dexamethasone suppression test) may be warranted.



PATIENT

Max Smith

- Also consider three-view thoracic radiographs to assess for occult disease in the chest that may be associated with the patient's inappetence.

ADDENDUM

The following information was provided on 8/4/23:

SPECIES

Canine

- ALT 143(10-125)
- ALP greater than 2000(23-212)
- GGT normal
- Total bilirubin normal

BREED

Dachshund

Based on this additional information, the recommendations initially provided remain the same.

SEX

Neutered Male

Andrea Nicastro
MPH, DVM, DACVIM
Sonopath

AGE

14 years

WEIGHT

8.24 kg

INTERPRETED BY

Andrea Nicastro, DVM,
Diplomate ACVIM (*Small Animal Internal Medicine*)

IMAGING PERFORMED BY

Crystal Hill

HOSPITAL NAME

Hartzel AH

REFERRING VET

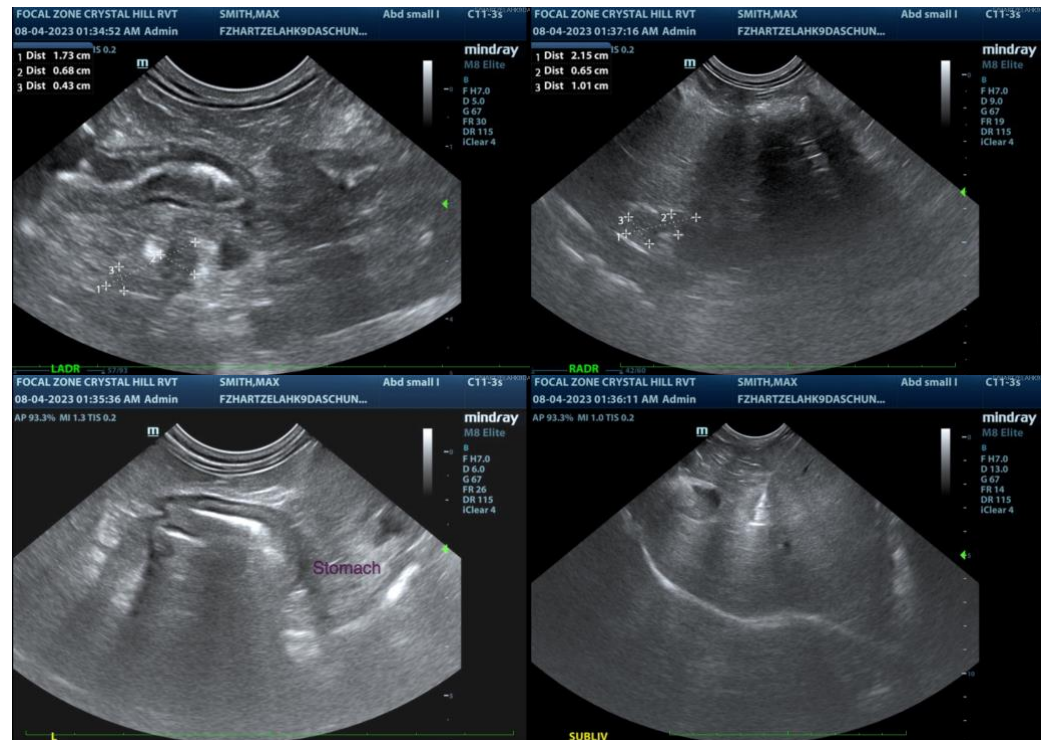
Morris

INVOICE

13949

DATE

8.3.23





PATIENT

Max Smith

SPECIES

Canine

BREED

Dachshund

SEX

Neutered Male

AGE

14 years

WEIGHT

8.24 kg

INTERPRETED BY

Andrea Nicastro, DVM,
Diplomate ACVIM (*Small
Animal Internal Medicine*)

**IMAGING
PERFORMED BY**

Crystal Hill

HOSPITAL NAME

Hartzel AH

REFERRING VET

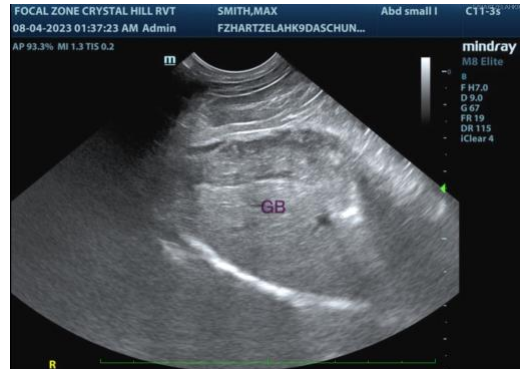Morris

INVOICE

13949

DATE

8.3.23



The information and recommendations provided are based on the images presented by the referring veterinarian/sonographer. No evaluation can be communicated regarding pathology that was not visible in the image/video clips provided.

Thank you for this referral. If the clinical or image interpretation does not parallel your findings or if I can be of any further assistance, please contact me.

Andrea Nicastro, MPH, DVM, Diplomate DACVIM (Small Animal Internal Medicine)
info@SonoPath.com